

Additional diagrams to the:

The European Society of Gynaecological Oncology (ESGO), the International Society for the Study of Vulvovaginal Disease (ISSVD), the European College for the Study of Vulval Disease (ECSVD), and the European Federation for Colposcopy (EFC) consensus statement on the management of vaginal intraepithelial neoplasia

Vesna Kesic ,¹ Xavier Carcopino,² Mario Preti ,³ Pedro Vieira-Baptista ,^{4,5} Federica Bevilacqua,³ Jacob Bornstein,⁶ Cyrus Chargari ,⁷ Maggie Cruickshank,⁸ Emre Erzeneoglu,⁹ Niccolò Gallio,³ Murat Gultekin ,¹⁰ Debra Heller,¹¹ Elmar Joura,¹² Maria Kyrgiou,^{13,14} Tatjana Madić,¹⁵ François Planchamp ,¹⁶ Sigrid Regauer,¹⁷ Olaf Reich,¹⁸ Bilal Esat Temiz,⁹ Linn Woelber,^{19,20} Jana Zodzika,²¹ Colleen Stockdale²²

by

Maciej Stukan, MD, PhD

ESGO member,

Pomeranian Hospitals, Gdynia, Poland

Department of Gynecological Oncology

VaIN 2/3 treatment

Cold knife
Laser CO2
CUSA
LEEP



Laser vaporization CO2
PDT
Electrocoagulation



Imiquimod
5-FU
TCAA



Brachytherapy



histology



occult carcinoma
2,6-30%



risk of vagina
shortening,
obstruction



multifocal



efficacy

66 - 88%

71 - 91%

76 - 92%

86.4 - 93%

recurrence

7.2 - 25%

31 - 57%

even 61%

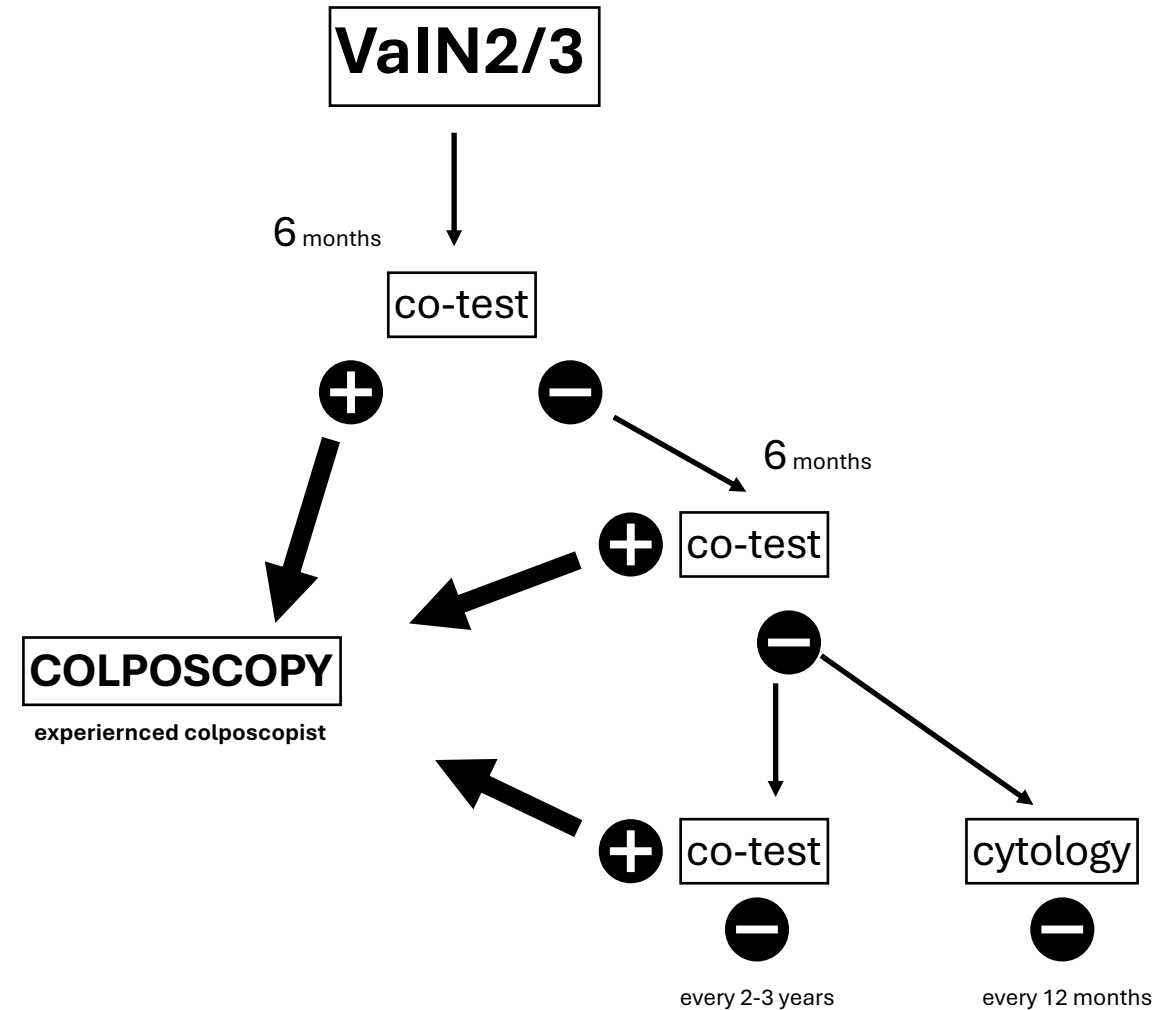
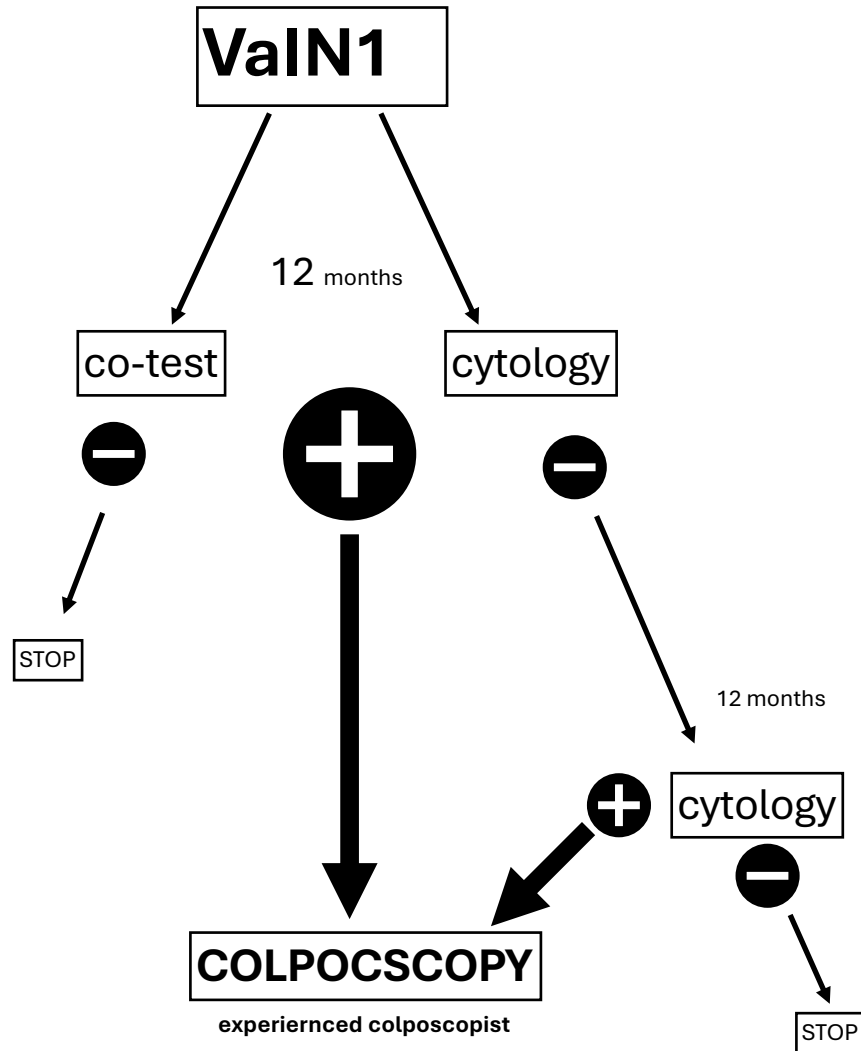
7,3%

Based on:

To cite: Kesic V, Carcopino X, Preti M, et al. *Int J Gynecol Cancer* 2023;**33**:446–461.

Follow-up after treatment of VaIN

Based on: **To cite:** Kesic V, Carcopino X, Preti M, et al. *Int J Gynecol Cancer* 2023;33:446–461.



Legend: **+** = every positive result